



## Some Morphological Changes in the Structure of the Heart

Mirsharopov U.M

Tashkent Medical Academy

Abdikadirov Sh.I.,

Tashkent Medical Academy

Akhmedova S.M.

Tashkent Medical Academy

### ABSTRACT

The aim of our work is to identify features of morphogenesis in postnatal development, the study of the histological structure of different departments and membranes of rat heart at 1-22 days after birth. The object of the study was the heart of the 50 rats at 1, 6, 11, 16, 22 days after birth. Notes alternating periods of acceleration and deceleration of the growth rate increasing thickness of the atria and ventricles. Endocardial and epicardial thickness increases significantly less. The growth rate of the thickness of the ventricular myocardium were observed in rats 6 and 16 days of age. Structural changes occur due to the growth of the organism. Feature of the structure and topography of microvessels heart is their distribution in the course of cardiomyocytes and the relationship with fibrous connective tissue structures of cardiomyocytes.

### Keywords:

rat heart, postnatal ontogenesis, cardiomyocytes, fibrous structure atria and ventricles.

**Topicality.** Heart variability is not only general biological interest, but has a certain significance in the disclosure of physiological processes developing therein, depending on the environmental conditions. According to the World Health Organization (WHO), cardiovascular system diseases often lead to disability of the able-bodied population and it takes leading place in the structure of causes of death around the world. Annually 17,5 million people die from cardiovascular system diseases which consists approximately 29% from all death cases. If in Europe from cardio vascular system pathology die 4 million people that this index in the USA is 37,3%, in Russia 57%, in India 60%. Therefore, today in the world medicine has been paid special attention to diagnose and develop modern treatment system of cardio vascular system diseases. Every year in the Republic of Uzbekistan, 8000 people are being registered with the state of myocardial infarction, 60% of them die in the pre hospital stage. According to statistics, the

mortality from cardiovascular diseases in Uzbekistan is 58% of the total mortality and in 20-50% of cases we observe sudden death case. It is very important prophylactic measures [2,7,9,10]. Worldwide to achieve high efficacy in agriculture it is important carry out oriented studies use of pesticides, which have different chemical compounds.

**The purpose of the study** is the evaluation microscopic and morphometric changes in the various layers of the walls of the atria and ventricles of the heart during early postnatal ontogenesis under the influence of pesticides.

**Material and research methods.** Research has scientifically substantiated with the results of inspections conducted on 180 white laboratory rats during early postnatal ontogenesis. Animals were divided into 3 groups. In the first group after the birth of infant rats to mothers introduced pesticide cotoran daily dose of 1/100 LD50

intragastrically through a catheter. In the second group in the same way to female rats administered kinmiks pesticide in dose maximum allowable level 5, and the infant rats were anesthetized in the above age periods. In the control group of female rats daily in the morning on an empty stomach, depending on the period, distilled water was administered in an amount of 1 ml. As a probe for the female rats used subclavian catheters №1. Rats were anesthetized by Rausch-narcosis at 1, 6, 11, 16, 21 days after birth. In the complex morphological studies, which includes in its membership general histologic, histochemical techniques organometri, morphometry, scanning electron microscopy, transmission electron microscopy, ECG heart and mathematical modeling and forecasting toxic myocarditis it was used.

After removal from the thorax the made measurements of length, width and thickness of rat heart. To determine the linear dimensions were used caliper with 0.05 mm scale. Heart length measured from the tip to the outermost part of the base of the heart. Heart width defined as the distance between the protruding portions at atrioventricular sulci from left to right. The thickness of the heart - the distance between the most prominent parts on the level of atrioventricular sulci from front to back. Heart shape is determined visually. To determine the mass and weight of the rat hearts were used electronic scales.

Histological sections of 8-10 microns thick, made with the help of a microtome, were stained with hematoxylin and eosin by standard methods. Collagen fibers in the connective tissue shell of the walls of the heart revealed by pikrofuksin by the method of Van Gieson, elastic fibers by the method of Weigert and reticular fibers by Foote modification N.A. Yurina.

For scanning electron microscopy infarction size pieces 1,5x1,5 mm are fixed in 2.5% glutar aldehyde solution, with pre fixing osmium tetroxide in phosphate buffer, dehydrated in alcohol-acetone, and dried by the critical point in the apparatus NSR-2. Deposition of gold held in the apparatus of IB-2 and examined in electron microscope JEOL

JSM-6010LV and Hitachi-S405 with photographing the monitor screen using the latest Canon digital camera.

Received the results of the research data were subjected to statistical processing on a computer Pentium - IV using the software Microsoft Office Excel-2012 package with statistical processing functions. The micrographs obtained drugs on the microscope 11 and Mikromed-3 with photo and video consoles Tucsen Camera TCA-5.0C China.

### **Research and discussion results.**

Significant increase in the thickness of left and right endocardial atrium observed in all development time (1-, 6-, 11-, 16-, 21-th day) and ranged from 8% (in the right atrium at the 16th day) to 29%. Results of the study of myocardial thickness showed that the growth rate of myocardial thickness in all study periods increased rapidly from 13% to 29%. Especially on the 6th day by 25% in the top and bottom of the left ventricle by 24% and the top and bottom of the right ventricle. A significant increase in the thickness of the myocardium of the left and right atrium was observed in all of time (1-, 6-, 11-, 16-, 21-th day), and ranged from 12% (in the right atrium at the 6th and 16th day) to 22% (in the left atrium at 11- and 21st day). The growth rate of the thickness of the epicardium of the left and right ventricles showed that the thickness of the epicardium at all time compared to previous periods increases slightly, ranging from 8.2% to 11.5%. These figures in the left and right atrium are from 9% to 18%.

In the dynamics of early postnatal ontogenesis check in intact rats histological structure of the structural elements of the cardiac atria and ventricle layers showed a definite pattern of development and differentiation. In the early stages of the study (at the 6th and 11th day) structural elements of all layers of the heart wall remain undifferentiated, especially better observed in the myocardium where cellular elements predominate over the myofibrils. At a later date check on the 21-day structural elements of all layers of the heart wall become their true

morphological and functional features and fully formed.

The left and right ventricles distinguishes subendocardial, subepicardial and intermediate layers. Subendocardial layer of the myocardium is more differentiated than the other layers, and consists of parallel beams of cardiac hystiocyte, running parallel to the endothelium. Subepicardial myocardial layer has a loose structure and has bundle form, cardiomyocyte it arranged randomly and are larger. In individual cardiomyocyte myofibrils thicker in others - a vague and vacuolated (Figure 1.). The intramural layer of left ventricular myocardial muscle cells are arranged perpendicular to the subendocardial layer. The interventricular septum myocardium heart denser, thicker form cardiomyocyte parallel beams. Around cardiac hystiocytes and around the vessels are arranged bundles of collagen and elastin fibers. Reticular fibers are arranged between the cardiomyocyte as a dark brown fibrous structures that envelop the individual muscle bundles, forming large loop (Figure 2.), And around the vessels in the epicardium - small loop network.

Intramural myocardial layer is presented in parallel reaching myofibrils which significantly prevail over the nuclear structures. Subepicardial layer compared to other layers composed of thin and cut transversely cardiac hystiocytes, between which the arterial and venous vessels. This venous sinuses have different shape and size, some of them form large elongated blood lake. In the histochemical method checking by Van

Gieson in the walls of arteries, arterioles revealed large bundles of collagen fibers. And in the walls of the veins and in the stroma of the myocardium - tender and broken collagen fibers. Especially it thickens subendothelial inner elastic membrane, which is represented by a thick winding material of uneven thickness deep purple color. The muscular and adventitial layers of artery walls elastic type of elastic fibers is small, and they are presented in the form of bluish shadow structures.

Arterioles rat heart characterized by a thin inner layer, a distinct middle and outer layers. The inner layer consists of arterioles located close to each other nuclei of endothelial cells. A well-developed middle membrane consists of a circularly-directed bundles of muscle fibers. They form two layers. The inner diameter of the arterioles newborn rats control group averages  $11,7 \pm 0,6$  m. Up to 6 days there is the greatest pace of growth arteriolar diameter and is 40%, and in the subsequent age groups the growth rate of the inner diameter of the arterioles slightly.

Capillaries have a diameter in average  $4,7 \pm 0,6$  microns. The inner layer is composed of the capillary walls of endothelial cells, the middle layer - of the basement membrane and the external elastic membrane. Mainly found in the capillaries of the myocardium reveals in sub epicardial layer. The subendocardial layer of blood vessels are rare. The wall consists of venular endothelial cells, which are located at a great distance from each other. The muscular layer venules underdeveloped. Thickness venules averages  $16,7 \pm 1,2$  m.

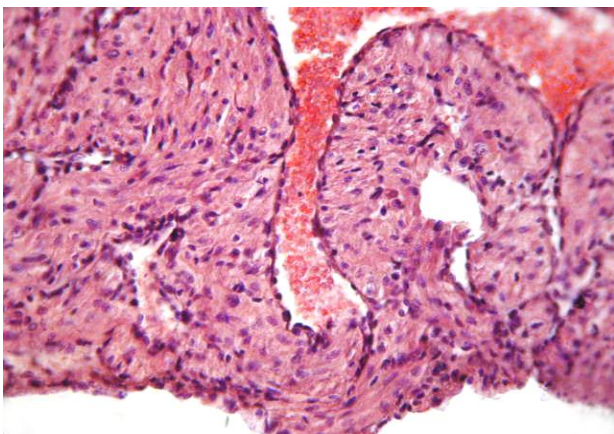


Figure 1. Cardiomyocytes different shapes and staining power. Colour: hematoxylin

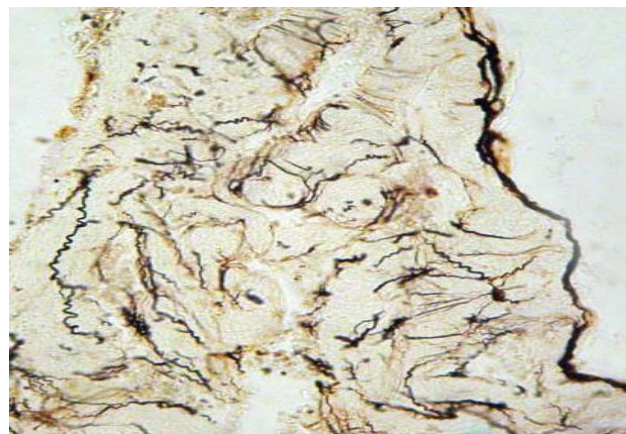

Figure 2. Small loop wale network of reticular fibers of the myocardium. Colour:

eosin.

by Foote.

The results of morphometric studies in rats ventricular in breast-feeding showed that the initial period of the experiment the thickness of the walls of all the departments less as compared with the control group. It is established that a pronounced lag ventricular wall thickness was observed on the 11th day: it was less of a benchmark to 31%. The smallest changes were found at day 21, whereas figures experimental group were below 4% to 19% compared with the control group. Comparison of the left thickness and the right atrium to the control group showed that in all experimental periods endocardium and the myocardium thickness was less from the benchmark of 6% to 23%. The difference data of the left and the right atrium is not established. The thickness of an epicardium benchmark less than 2% to 11.5%.

Morphometric results of inspections of different diameter blood vessels of the heart wall of rats during feeding breast milk under the influence of cotoran has shown that since the 6th day with a decrease in the internal diameter of arterial vessels contracted. At 6 days of age artery diameter is on average  $49.8 \pm 4.3$  microns, which is less than the reference index by 12.3% at 11 days of age -  $52.5 \pm 5.6$  microns, which is lower than normal on 8 8%, in 16 days -  $56,7 \pm 6,3$  m, which is also less than the rate of 11.2% in 21 days -  $61,3 \pm 7,3$  m, which is less than the norm of 7.6 %. It may be noted that with age, the diameter of the artery of the heart is increased, but compared with the norm revealed some of its backlog. At different times the research dynamics of changes in arteriolar diameter is just a trend: the study of the figure in all terms retained decrease compared with the control group.

Born from the poisoned Cotoran and kinmiks in female rats during early postnatal ontogenesis the microscopic tests have shown that pathological changes in the structural elements of the heart are manifested in the form of edema-dys circulator processes,

dystrophic degenerative -and-destructive inflammation.

Initially pathomorphological changes in vessels exposed microcirculatory system, then the venous vessels and in the end of the experiment (day 21) changes encompassed artery. In the small blood vessels of the heart revealed hyperemia, stasis and diapedetic hemorrhage, accompanied by perivascular edema, swelling and disorganization of connective tissue stroma.

Dyscirculatory violations extended to venous vessels in the form of enhancement and hyperemia, development of perivascular edema and hemorrhage diapedetic, which are the result of the toxic effects of pesticides, as a result of developing dys circulation of microcirculatory vessel toxic venous plethora and increased vascular permeability. Increased microvascular permeability and venous vessel level was accompanied by the release of the liquid portion of the blood through the wall of the vessel to the surrounding connective tissue. As a result, amorphous material with the redistribution of glycosaminoglycans, hyperacidity and hydrophilic fabrics change the quality and quantity of tissue fluid, which leads to the development of a disruption of cellular and fibrous structures vascular and stromal tissue, and this is manifested in the form of mucoid and fibrinoid swelling of fibrous structures. Specifically, these changes in the heart first cover vessel wall and perivascular connective tissue. Fibrinoid swelling of the fibrous structures is accompanied by the emergence of alterative changes, which develop in front of inflammatory and hyperplastic processes.

In our study, the inflammatory process peaked in the 16th day of the study, appearing perivascular and interstitial lympho histiocytic infiltrate. The appearance of proliferative tissue infiltration shows the development of chronic inflammation, which is an autoimmune nature. It is known that cell proliferation lymphohistiocytic primarily associated with

the development of hyperplastic proliferation processes as originally granulation and connective tissue and then leads to a thickening of the vascular-stromal interstitial stroma that is detected by the histochemical method of Van Gieson. This fixed vacuum decay and reticular fibers intramuscular interstitial, and vascular wall observed uneven thickening. The above mentioned changes in the vascular stromal tissue of the heart leads to metabolic disorders in the parenchymal cells or cardiac hystiocyte. Morphologically these disorders in cardiomyocyte, were manifested in the form of protein hyaline droplet and vacuolar degeneration, which in our observations often localized in the perivascular areas and subendocardial layer of the myocardium.

The study of morphometric data of the left and right atria and ventricles of the experimental groups revealed decrease in all parts of the heart wall under kinmiks. It is established that a pronounced lag thickness of the ventricular wall is observed on the 11th day: it was less from control index to 60%. The biggest change was subjected the myocardium of the left ventricle. Particularly, these changes detected in the bottom of the ventricles. Along with this, under the action kinmiks thickness of endocardium of the right ventricle and the left at the top and bottom is less than 20% to 35% compared with the control group. A comparison of the left and right atrium thickness with the control group showed that the most pronounced growth lag behind the walls of the heart in rats at exposure with kinmiks detected in animals in the 16-day experiment.

The thickness of the myocardium of the left and the right atrium reduced by 23-29%. In all experimental periods of atrial endocardial thickness was less than the control index of 6% - 19%. The thickness of an epicardium less than control index 2% - 11.5%. The results of microscopic examination of the infant rat's heart during lactation under the effect of kinmiks to female rats shown that, as in the exposure of cotoran in this series of experiments pathomorphological changes in structural heart cells also manifested as edema-dyscirculatory, dystrophic, degenerative and

inflammatory-destructive phenomena, but unlike the previous series, these processes were expressed more strong.

In this group of the study of dyscirculatory violations extended to venous vessels in the form of enhancement and hyperemia, development of perivascular edema and diapedetic hemorrhage, which are the result of the toxic effects of pesticides, as a result of the developing decirculation of microcirculatory vessel, toxic venous plethora and the increase of vascular permeability.

Fibrinoid swelling of the fibrous structures is accompanied by the emergence of alterative changes, against to others develops inflammatory and hyperplastic process. The appearance in the tissues of the proliferative infiltrate suggests a chronic autoimmune inflammatory nature. It is known that cell proliferation of lymphohistiocytic primarily accompanied by the development of hyperplastic proliferation processes as originally granulated, then connective tissue, and then led to thickening of vascular-stromal interstitial stroma.

Obtained morphological data about violation of cardiomyocyte contractile function of the mitochondrial damage in violation of energy and metabolic processes that lead to necrobiosis, changes in micro vessels with violation of the transport function of the endothelium and other components of the vascular wall.

Studies to identify the impact of pesticides on myocardial ultrastructure with preliminary study of half-sections slices with the use of scanning microscopy and transmission electron microscopy showed that the character of myocardial changes in rats exposed to cotoran or kinmiks through the mother's milk is almost the same.

In the early stages (6-11 day) recorded strong changes expressed by ultrastructural changes in cardiomyocyte myofibrils, which reveal a violation of the contractile function of these cells. It leads to violations of the three-dimensional structure of the muscle fibers of the myocardium.

**Conclusion.**

The maximum increase in length, width and anteroposterior heart size observed from birth to 6th day and changes its location cranio-caudal direction. From the moment of birth until 21 days of age, the ratio of the relative weight of the heart to the body weight is reduced from 1.75% to 1.1%. There is a relationship between the coefficient of comparative changes in heart mass and body, as well as changes in heart shape and development of the chest. Revealed the presence of specific patterns in the histological structure, comparative perfection of the structural elements of the atrial wall and ventricular dynamics control rats in early postnatal ontogenesis. The toxic effects of pesticides on the heart of rats demonstrated specific pathological morphological changes, that is, there was disorganization of fibrous structures in the wall of arterioles and capillaries, proliferation own connective cells and protein dystrophy muscle fibers of the myocardium, and loosening discomplexation of myofibrils violation of the nuclear-cytoplasmic ratio. It is proved that in the control infant rats, depending on their age periods, there are morphometric and histo topographic peculiarities particularly in the structural elements of all layers of the wall of the atria and ventricles of the heart. However, it is proved and morphometric parameters significant reduction in atrial wall layers and ventricles in experimental animals as compared to controls. It was revealed that the cotoran and kinmiks, affecting the ultrastructural elements of the heart, lead to a change rate in myofibrils, violation of energy and metabolic processes that lead to necrobiosis in the mitochondria, disruption of the transport function of the endothelium and the inner layers of the walls of small blood vessels, resulting in the observed development of intracellular and intermediate tumor tissue. Changes in ECG were characterized by the emergence of a variety of disorders of rhythm and conduction of the heart. In the later stages of the experiment in the myocardium were observed changes in the form of necrosis. Necrosis was reflected in the QRS complex. Mathematical modeling, created to predict

toxic myocarditis heart based on morphometric data, the coefficient  $\beta$  - the ratio of stroma and parenchyma infarction and mutual relations Scaled clinical symptoms to diagnose and determine the extent of myocardial diseases.

## References

1. Akhmedova S.M. Morphological characteristics of the development of the walls of the heart of rat pups. *Science and Peace*. 2015; 1(7): 85-87.
2. Akhmedova S. M. Creation of the informational model of toxic myocarditis occurred under the influence of pesticides // *European science review*, Austria, Vienna, 2015. - № 11-12. - P. 61-63
3. Akhmedova S. M. Histological structure of rat heart in the early stages of ontogeny // *European science review*, Austria, Vienna, 2016. - № 5-6. - P. 30-33.
4. Akhmedova S.M., Mirsharapov U.M. Some morphofunctional changes of heart at the influence of pesticides. *Bulletin of the Doctor* No. 2—2018: 15-18
5. Bokeria O.L., Akhobekov A.A. Sudden cardiac death: mechanisms of occurrence and risk stratification. *Annals of arrhythmology*. 2012; 3:5-13.
6. Boldueva S.A. , Shabrov A.V., Lebedev D.S. Prognosis and prevention of sudden cardiac death in patients with myocardial infarction. *Cardiovascular therapy and prevention*. 2008; 7(3): 56-62.
7. Gorbunov A.A. Connective tissue component of the myocardium: a new stage in the study of a long-standing problem. *Morphology*. 2007; 4:6-12.
8. Kurbanov R.D., Mullabaeva G.U., Kilichev A.A., Kevorkova Yu.G., Saifitdinova N.B. Efficacy of ivabradine in the treatment of patients with Q-wave myocardial infarction. *Cardiology of Uzbekistan*. 2014; 3:11-16.
9. Lebedinets A.N., Voloshin N.A., Chugin S.V. Dynamics of the structural

components of the rat heart in the postnatal period after intrauterine exposure to antigens of various nature. Pathology. 2011; 2:43–45.

10. Michela N. F. Inform the Heart: Control of Cardiomyocyte Cycling and Size by Age-Dependent Paracrine Signals Developmental Cell. 2009; 16:161.